Original Article
Acta of Shoulder and Elbow Surgery 2017 July - Dec;2(2): 9-11

Anterior instability of the shoulder with more than 10 years evolution, treated with Latarjet Procedure, long-term results

Domingo Beltramelli[1], Mauricio Oehler[2], Bruno Pintos[2], Emerson Kucharski[2], Viviana Teske[2]

Abstract

Background: The purpose of this study is to make a retrospective evaluation of the long-term evolution of patients who were operated using the Latarjet in order to evaluate the results regarding the rate of recurrence and arthrosis in the series taken.

Materials and Methods: We considered 58 patients who were operated more than 10 years ago using Latarjet procedure, average follow-up of 13,8 years. The average age at the time of the surgery was 27 years old, 46 of them were males and 12 females and 39 of the total had their dominant side affected. 33 practiced sports, 18 professionally and 15 as a spare time activity. In 22 cases the technique was performed using one screw, and in 36 cases were used two screws.

Results: Using the Carter Rowe scale for the functional evaluation, from a preoperative average of 38,5 we reached 88,2 at the end of follow-up. The recurrence was 5,7%. All the cases show glenoid bone injury that were reviewed using preoperative x-ray which were considered to compare with current evolving x-ray analyzing arthrosis with the Samilson-Prieto criteria. Only 2 patients showed arthrosis in stage 1 in the preoperative. At the time of the evaluation 18% show arthrosis, 2 cases in stage 3, 4 in stage 2 and 4 cases in stage 1. From the ones that practiced sports professionally, 15 resume their activity, and from the ones practicing sports recreationally, 10 resume it.

Conclusions: The Latarjet procedure shows excellent results to treat anterior instability of the shoulder in the long-term. The levels of recurrence and arthrosis are low.

Level of evidence: Level 4. Case Series. Treatment Study.

Keywords: Latarjet procedure, anterior instability of the shoulder, arthrosis.

Introduction

Since the 1980s the Latarjet procedure (6, 7) has been used in Uruguay in cases of anterior shoulder instability with bone injury. Firstly it was performed with one screw and with tenotomy of the subscapularis muscle. In 1995 we started to perform the procedure with two screws and the dislocation of the subscapularis muscle without tenotomy, as described by Gilles Walch (12, 13,16). After the controversy generated by this procedure and its complications, numerous studies have been carried out approaching the stabilizing mechanisms and indications; with instrumental design, and currently with the performance of the Latarjet arthroscopy technique (5).

The purpose of this study is to make a retrospective evaluation of the long-term evolution of patients who were operated using the Latarjet in order to evaluate the results regarding the rate of recurrence and arthrosis in the series taken.

Materials and Methods

Ethical committee approval was taken for this research. From a total of 63 operated patients, 58 were clinically and radiologically evaluated. Five patients were lost to follow up. None of the patients in this series had bilateral shoulder instability. The average follow-up was 13.8 years, ranging from 10 to 21 years. The age at the time of the surgery goes from 18 to 43 years old, with an average of 27.3 years. There were 46 males and 12 females. 39 of the total had their dominant side affected. 33 practiced sports, 18 professionally and 15 as a spare time activity.

All the patients were operated by surgeons of the Group of Shoulder of Montevideo, using the same clinical (C. Rowe) and radiological evaluation criteria (front neutral rotation and intern rotation and profile of Bernageau-Patte (2, 9) in pre and postoperative. Fig.1y 2.

The surgeries were performed with the patients placed in the beach chair position, through straight anterior approach, with delto pectoral dissection, the cephalic vein stayed next to the deltoids, with osteotomy of the coracoid, subscapularis split approach and fixation with malleolar screws of 3.5 mm. Fig.3and 4. In 22 cases the technique was performed using one screw, and in 36 cases were used 2 screws. In those patients who were under the age of 40 the anterior capsule was closed by suture remaining on the medial aspect of the coracoid graft.

Results

We used the Carter Rowe scale [10] for the functional evaluation, from a preoperative average of 38,8, at the end of the follow up it

[1] Jef of Shoulder Group Montevideo Uruguay and CASMU Hospital
[2] Shoulder Group and CASMU Hospital Montevideo Uruguay
Address of Correspondence
Dr. Alexandre de Almeida:
Rua Vitório Buzelatto, 222/601. Caxias do Sul, RS, Brazil.
Zip: 95020290.
E-mail: bone@visao.com.br

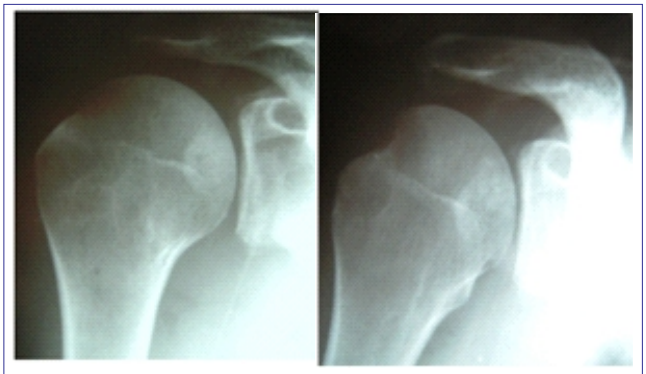

Figure 1: anterior-posterior view, newtural and internal rotaion.

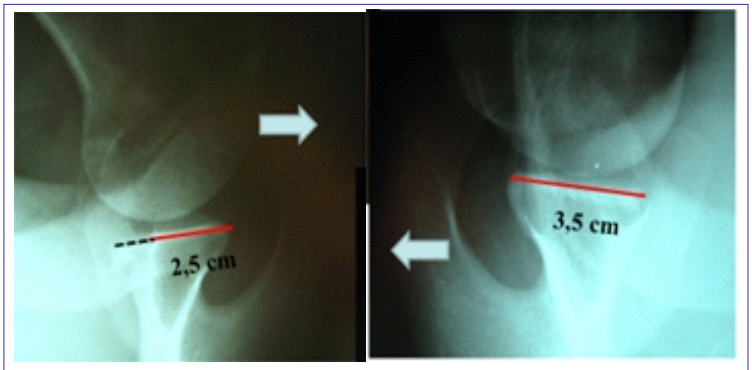

Figure 2: The surgeries were performed with the patients placed in the beach chair position, through straight anterior approach, with delto pectoral.

rises to 88,2 (p<.001) [1, 4, 8]. In 3 of the cases there was recurrence, all of them showed this in the first year of postoperative evolution. In one case there was a new traumatic episode with tearing of the coracoid and broken screws. In 2 cases the coracoid was more than 5 mm medial and showed subluxation that did not required surgery though it kept them from playing sports as they previously did.

All the patients showed bone injury of the glenoid, 20 (34,5%) cases with minor bony injury, 22 (38%) with a 10 to 20% bony injury and 16 (27,5%) showed bony injuries over 20%. The glenoid injury was always assessed with the Bernageau- Patte bilateral comparative profile view (Fig.5). In 42 shoulders (72,5%) Hill Sach injury was seen.

The arthrosis was evaluated with Samilson – Prieto classification [11], studied with X-ray anterior-posterior view, with neutral and internal preoperative rotation that were used to compare current evolving radiographies. Only 2 (3,5%) patients had arthrosis in stage 1 in preoperative, and at the time of the evaluation 10 (18%) patients showed arthrosis; 2 (3,5%) cases in stage 3; 4 (7%) in stage 2 and 4 (7%) in stage 1. The pain was evaluated with EVA and the results show that the 2 patients in stage 3 of Samilson – Prieto presented 5 and 6 points respectively; the ones in stage 2 all showed EVA between 3 and 4 points and the 4 patients in stage 1 showed very light pain occasionally.

From the 33 patient that practiced sports, 15 of the ones that practiced sports professionally resume their activity, and from the ones practicing sports recreational, 10 resume it.

Discussion

Since the 1954 description of this Latarjet procedure, it has been used for the treatment of anterior instability of the shoulder. All the studies and our research show that this is an excellent technique for the stabilization of the unstable shoulder with a low percentage of recurrence (5.1%). It is important to highlight that all the cases that showed recurrence were among the first year of postoperative evolution and this number did not increase after the second year as it happens with other techniques used for unstable shoulders.

Nowadays this is the most accepted procedure internationally to treat the anterior shoulder dislocation recurrence with bone injury. The Glenoid Track concept which is described by Itoi et al. show the bone instability in the glenoid and humeral head [15] (Fig. 6)

This a demanding though much regulated procedure. The complications (such as recurrence and arthrosis) are consequences of mistakes in the technique; with medial or lateral location of the coracoid graft.

We use the capsular reparation in patients younger than 40 years old as an adjuvant in stabilization and as an arthrosis preventive method interposing the capsule between the coracoid graft and the epiphysis [3].

Several studies show the triple stabilization of the Latarjet procedure: the bone effect of the coracoid, sling effect of the conjoint tendons and the subscapularis and the capsular effect [14].

Arthrosis is a degenerative process that starts with shoulder instability and will progress with or without surgery. All the surgical techniques cause arthrosis at some level. In the Latarjet procedure the arthrosis is caused by the lateralization of the coracoid graft.

Conclusions

The Latarjet procedure shows excellent results to treat anterior instability of the shoulder in the long-term. The levels of recurrence and arthrosis are low. The recurrence in our series appears during the first year of postoperative and the arthrosis increases due to a fail in the procedure with the lateralization of the coracoid.

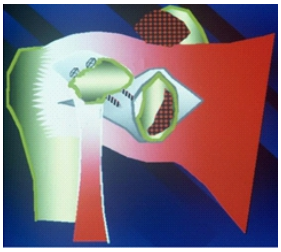

Figure 3: Subscapularis split approach

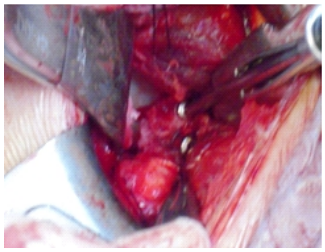

Figure 4: Fixation with malleolar screws of 3.5 mm

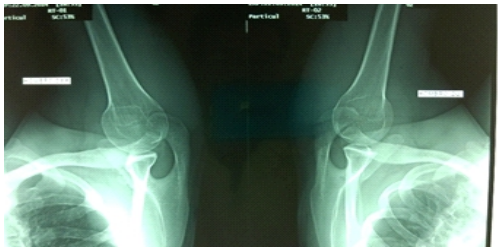

Figure 5: Glenoid injury was always assessed with the Bernageau- Patte bilateral comparative profile view

Figure 6: The Glenoid Track concept [15]

References

1-Allain J; Goutallier D; Glorion C. Long-term results of the Latarjet procedure for the treatment of anterior instability of the shoulder. J Bone Joint Surg Am 1998;80:841-52.

2-Bernageau J, Patte D, Debeyre J, Ferrane J. Interet du profile glenoidien dans le luxations recidivantes de l' epaule. Rev Chir Orthop 1976;62:142-7.

3-Burkhart SS; De Beer JF; Barth JR; Cresswell T; Roberts C; Richards DP. Results of modified Latarjet reconstruction in patients with anteroinferior instability and significant bone loss. Arthroscopy. 2007 Oct; 23(10);1033-41.

4-Hovelius L, Sandstrom B, Sundgren K, Saebo M. One hundred eighteen Bristow-Latarjet repairs, for recurrent anterior dislocation of the shoulder prospectively followed for fifteen years: study I-clinical results. J. Shoulder Elbow Surg 2004;13:509-16. http.//dx.doi.org/10.1016/j.jse.2004.02.013.

5-Lafosse L; Lejeune E; Bouchard A; Kakuda C; Gobezie R; Kochhar T. The arthroscopic Latarjet procedure for the treatmentof anterior shoulder instability and significant bone loss.arthroscopy. 2007. Nov;23(11);e1-5.Epub 2007 Oct 03.

6-Latarjet M. Treatment of recurrent dislocation of the shoulder. Lyon, Chir 1954;49; 994-7.

7-Latarjet M. Technique de la butée coracoidienne pré-glénoïdienne dans le traitement des luxations recidivantes de l' épaule. Lyon Chir 1958;54:604-7.

8-Mizuno N; Denard PJ; Raiss P; Melis B; Walch G. Long-term results of the Latarjet procedure for anterior instability of the shoulder. J. Shoulder Elbow Surg 2014: 7, 1691-99.

9-Patte D; Bancel P; Bernageau J. The vulnerable point of the glenoid rim. In: Bateman JE; Welsh RP; editors. Surgery of the shoulder: New York: Marcel Dekker; 1985.p.94-9.

10-Rowe CR, Zarins B, Ciullo JV. Recurrent anterior dislocation of the shoulder after surgical repair. Apparent causes of failure and treatment. J Bone Joint Surg. Am. 1984 Feb: 66(2):159-68.

11-Samilson RL, Prieto V. Dislocation arthropaty of 322 the shoulder. J Bone Joint Surg Am 1983;65:456-60.

12-Walch G. Chronic anterior glenohumeral instability. J Bone Joint Surg Br. 1996 Jul;78(4);670-7.

13-Walch G, Boileau P. Latarjet-Bristow procedure for recurrent anterior instability, Tech Shoulder Elbow Surg. 2000; 1(4): 256-61.

14-Yamamoto N; Muraki T; An KN; Sperling JW; Cofield RH; Itoi E; Walch G; Steinmann SP. The stabilizing mechanism of the Latarjet procedure. A cadaveric study. J Bone Joint Surg Am 2013;95:1390-7. http://dx.doi.org/10.2106/JBJS.L.00777.

15-Yamamoto N; Itoi E; Abe H; Minagawa H; Seki N; Shimada Y; Okada K; Contact between the glenoid and the humeral head in abduction, external rotation, and horizontal extension: a new concept of glenoid track. J Shoulder Elbow Surg, 2007 Sep Oct;16(5):649-56.Epub 2007 Jul 23.

16-Young AA; Maia R; Berhouet J; Walch G. Open Latarjet procedure for management of bone loss in anterior instability of the glenohumeral joint. J Shoulder Elbow Surg 2011;20:S61-9. http://dx.doi.org/10,1016/j.jse.2010.07.022.

Conflict of Interest: – NIL
Source of Support: NIL

How to Cite this Article

Beltramelli B, Oehler M, Pintos B, Kucharski E, Teske V. Anterior instability of the shoulder with more than 10 years evolution, treated with Latarjet Procedure, long-term results. Acta of Shoulder and Elbow Surger July - Dec 2017;2(2):9-11.