Dynamic Anatomy of Elbow Stability

Juan Del Castillo, Rodrigo Fratelli[1], Mauricio Oehler[1], Nicolás Casales[1], Viviana Teske[1], Domingo Beltramelli[1]

Abstract

Background: Elbow dislocation leads to varying degree of instabilities depending on the ligaments damaged and amount of damage to these ligaments. Various studies have noted role of these ligaments and present study is a dynamic cadaveric study to understand these instabilities better

Material and Methods: 10 cadaveric elbows maintained in 10% formaldehyde concentration were employed. Healthy joint upper limbs were prepared, and the elbow joint was further dissected. The different joint osseous and ligament stabilizers were sectioned by stages, and their implication on the stability of the elbow joint complex was recorded.

Results: Collateral ligaments were confirmed to be the main ligament stabilizers in the elbow. The lateral complex controls both varus and posterolateral stress. The medial collateral complex controls valgus stress, mainly thanks to its anterior bundle. The radial head plays a secondary role, controlling valgus stress once the medial collateral complex has been sectioned. Once radial head has been replaced, valgus stress stability is regained

Conclusion: The role of elbow stabilizers has been determined, and our results are consistent with those of international literature

Keywords: Elbow Instability, Cadaveric Study

Introduction

The stability of the elbow joint is the result of a fine interaction of both static and dynamic elements, which together make up a strong complex. The aim of which is to provide a joint with stability throughout all of its movement range (1,2). Static restrictions are determined by the capsule, the lateral and medial ligaments complex, the radiocapitellar and ulnohumeral joint. The ligament complex and the ulnohumeral joint are the main static stabilizers of the latter. The muscles crossing the elbow joint are the dynamic stabilizers (2,3). It is widely known that, when elbow dislocation occurs, it is necessary to at least have an injury in the ligament complex, which can potentially result in residual instability, depending on the degree of the injury sustained (4). Several studies have contributed to the understanding of elbow biomechanics and its stabilizing factors. This paper depicts a dynamic cadaveric study on elbow stability, where the role of each main stabilizer is shown, as well as the result in the absence thereof, thus showing the resulting instability. The aim is to improve understanding of these injuries, thus optimizing treatment to prevent post-traumatic elbow instability.

Materials and Method:

The purpose of this paper is to study elbow stability through a dynamic study and to show the role of each joint stabilizer. The study was carried out in the Anatomy Department of the School of Medicine of Uruguay. 10 cadaveric elbows maintained in 10% formaldehyde concentration were employed. Healthy joint upper limbs were prepared and the elbow joint was further dissected. The different joint osseous and ligament stabilizers were sectioned by stages, and their implication on the stability of the elbow joint complex was recorded. Firstly, the anterior bundle from the medial collateral ligament was sectioned, and stress was performed on varus valgus; joint amplitude and stability were recorded and further compared to those of a healthy elbow. Next, the same was done with the lateral collateral ligament sectioning the lateral ligament and after performing equal stress on varus valgus; both amplitude and stability were recorded and further compared to those of a healthy elbow. Further, osseous stability was assessed by performing radial head excision; varus valgus and posterolateral stress was performed, thus assessing the implication of the head as secondary stabilizer. Proximal radial migration was also determined after radial head resection with healthy interosseous membrane. Further, cement spacer is placed a technique widely used locally

[1]Departamento de Anatomía Facultad de Medicina UdelaR (Anatomy Department, School of Medicine, University of the Republic of Uruguay

Address of Correspondence
Dr. Juan Del Castillo
Departamento de Anatomía Facultad de Medicina UdelaR (Anatomy Department, School of Medicine, University of the Republic of Uruguay
Email:btorres@ceoecuador.com.

© 2017 by Acta of Shoulder and Elbow Surgery | Available on www.asesournal.com | doi:10.13107/ases.2457-0338.2017.084
This is an Open Access article distributed under the terms of the Creative Commons Attribution Non-Commercial License (http://creativecommons.org/licenses/by-nc/3.0) which permits unrestricted non-commercial use, distribution, and reproduction in any medium, provided the original work is properly cited.

Figure 1: Elbow sagittal view

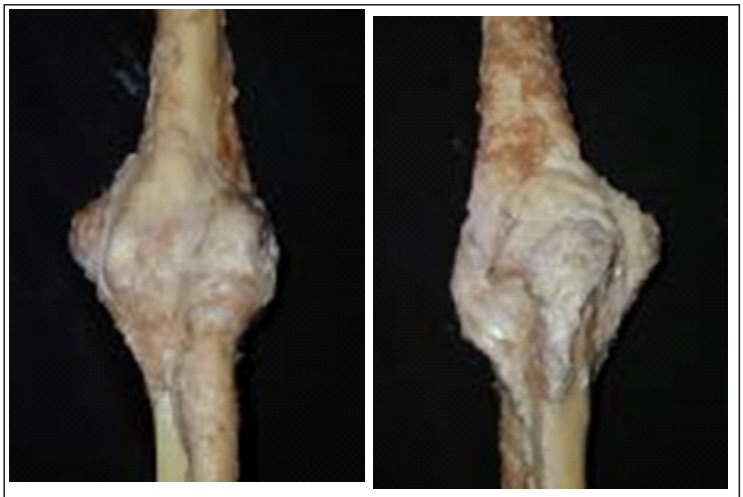

Figure 2: Anterior capsule (left) and posterior capsule (right).

to treat radial head fractures that cannot be affixed through osteosynthesis and the resulting stability after replacement was assessed.

Results: Collateral ligaments were confirmed to be the main ligament stabilizers in the elbow. The lateral complex controls both varus and posterolateral stress. The medial collateral complex controls valgus stress, mainly thanks to its anterior bundle. The radial head plays a secondary role, controlling valgus stress once the medial collateral complex has been sectioned. Once radial head has been replaced, valgus stress stability is regained.

Figure 3.: Specimen of Medial Collateral Ligament employed

Conclusion: The role of elbow stabilizers has been determined, and our results are consistent with those of international literature. Elbow stability is divided as 50% osseous and 50% ligamentous. In any dislocation episode, the key for a successful treatment is to diagnose which stabilizers have been compromised, in order to treat each of them accordingly, thus avoiding post-traumatic instability.

Figure 4: Specimen of Lateral Collateral ligament employed

Figure 4: Radial head excision and replacement with cement spacer

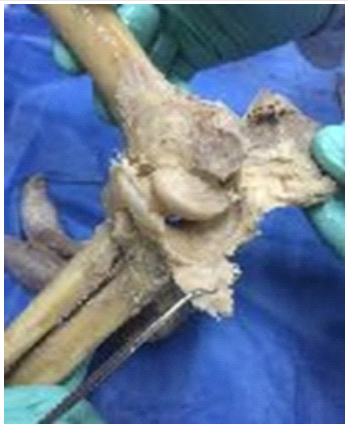

Figure 2: Valgus stress instability is shown once collateral ligaments ave been sectioned and radial head excised

References

1 O'Driscoll SW, Jupiter JB, King GJ, et al. The unstable elbow. Instr Course Lect 2001;50:89–102.

2 Crhis D. Bryce; April D. Armstrong. Anatomy and Biomechanics of the elbow. Orthop Clin N Am 39 (2008 141-154)

3 Miller Mark, Thompson S. DeLee & Drez´s Orthopaedic Sports Medicine Principles and Practice 2015

4 Morrey B, The Elbow and its disorders, 3rd ed 2004

Conflict of Interest: – NIL
Source of Support: NIL

How to Cite this Article

Castillo JD, Fratelli R, Oehler M, Casales N, Teske V, Beltramelli D. Dynamic anatomy of elbow stability . Acta of Shoulder and Elbow Surgery July - Dec 2017;2(2):30-32